

Maria Bibiana Leroux\*

Dermatologist, Videocapillaroscopy expert, Former teacher at the National University of Rosario, Private practice. Rosario. Argentina

**Dates:** Received: 11 December, 2015; Accepted: 07 January, 2016; Published: 08 January, 2016

\***Corresponding author:** Leroux Maria Bibiana, Dermatologist, Videocapillaroscopy expert, Former teacher at the National University of Rosario, Private practice, Santiago 450. 2000. Rosario. Argentina, E-mail: leroux\_mb@hotmail.com

[www.peertechz.com](http://www.peertechz.com)

ISSN: 2455-8605

**Keywords:** Acrocyanosis; Nail fold capillaroscopy

## Letter to Editor

# Nail Fold Capillaroscopic Findings in Elderly Patient with Acrocyanosis

The video capillaroscopy is a noninvasive technique that permits the *in vivo* observation of the cutaneous microcirculation. The selected anatomical site is the nail fold. The first capillary line is arranged as a crown on the nail matrix. In normal subjects the capillary pattern show regular thin and delicate structures.

The patient's video capillaroscopy (200 X) showed both structure and capillary density preserved. Besides, mega capillaries, hemosiderin deposits due to microhemorrhage and increased intercapillary distance point. These microvascular alterations support an early diagnosis of systemic scleroderma. The pattern combining mega capillaries, micro hemorrhages and avascular areas are pathognomonic of SS (Table 1), (Figure 3-5) [2,5].

The RP in patients in whom it is an isolated sign, and presence of SS specific antibodies associated with nail fold pathologic capillaroscopy provides a 60 percent probability of developing SS than those that have a normal capillaroscopy and negative serology [2-4].

Consequently, the patient should be follow periodically in order to detect the outbreak of a systemic compromise.

## Dear Editor

The Raynaud's phenomenon (RP) is well known as the first sign of systemic scleroderma (SS) and related disorders. Its early diagnosis leads to a better understanding of the disease and favorable prognosis.

The acrocyanosis is an acrosyndrome differing physiologically and clinically, that can be due to vascular etiology, systemic diseases, drugs, infections or other causes.

We hereby present an elderly male patient, aged 62 years, with acrocyanosis with altered capillaroscopy, compatible with an early systemic scleroderma starting three months ago in the fingers. The patient is a heavy smoker of 40 daily cigarettes during several years, with a body mass index (BMI) of 20.7 with neither Raynaud's phenomenon nor acrosclerosis or rheumatoid disease. There is no evidence of traumatism, cancer or systemic infection.

Two months ago he presented an acute bacterial paronychia in the third finger of the right hand which is presently healing very well (Figures 1,2). Acrocyanosis due to low BMI, thromboangiitis obliterans and secondary RP were considered among the differential diagnosis.

The acrocyanosis due to low BMI is produced by impaired thermoregulation. Nevertheless, the patient had the same BMI for 10 years without presence of acrosyndrome. The thromboangiitis obliterans is frequent in adult males younger than 45 years that have been or are currently heavy smokers. Sometimes skin dystrophy is present. Eco Doppler of both hands was normal. Considering the late outbreak of the disorder and the absence of macro vascular alterations there are no reasons to support the diagnosis of thromboangiitis obliterans. The three characteristic phases of typical RP are absent and there is only acrocyanosis. However, since there are incomplete clinical RP the patient was studied according to its specific protocol that includes clinical assessment, auto antibodies and nail fold video capillaroscopy, both very useful for an early diagnosis of connective tissue disease, as well as differential diagnosis between primary and secondary RP. The immunological essays enabled the detection of anti-centromere antibodies that are biological markers of SS [1-4].

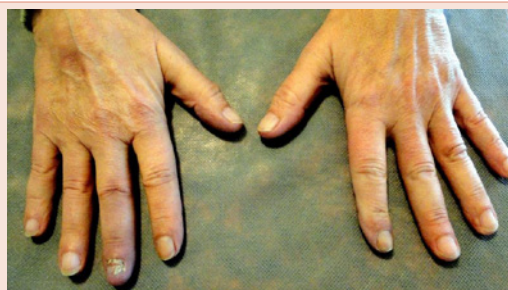

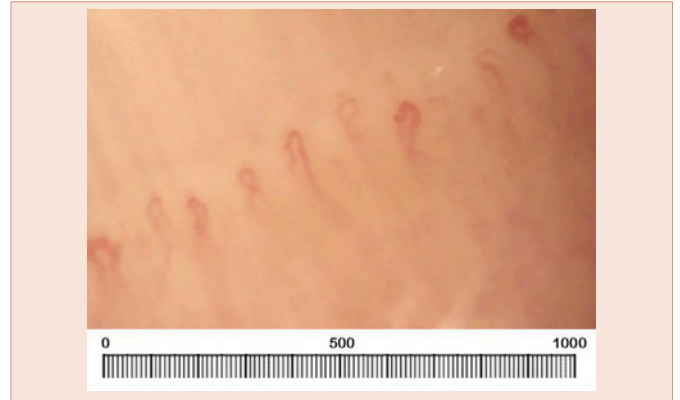
Figure 1: Acrocyanosis of the fingers and bacterial paronychia sequelae.

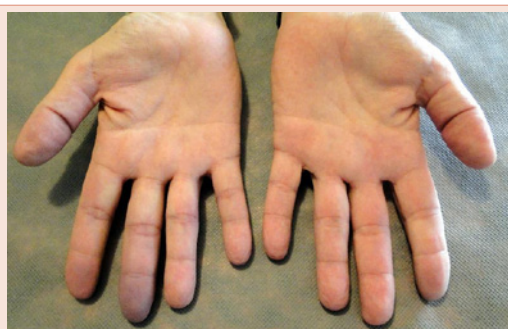

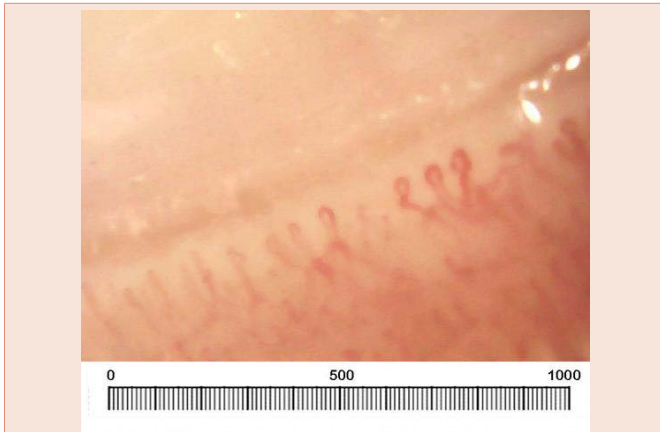
Figure 2: Palm of the hands.

**Table 1:** Capillaroscopy parameters.

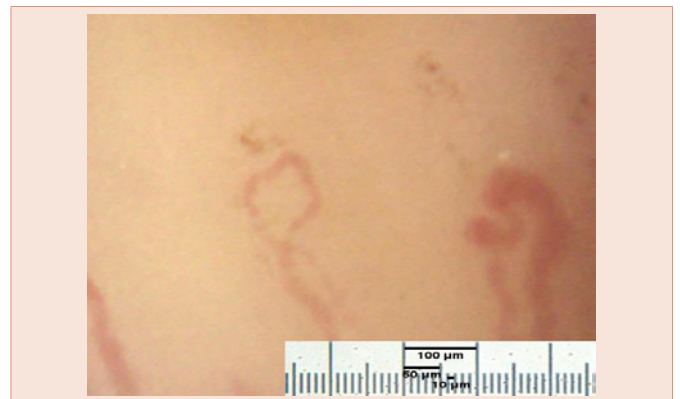
Parameters	Definition
Capillary Density	Capillary count along 1 mm of the first row of the nail matrix consisting in 7 – 17 per mm in normal subjects
Mega capillar	Giant capillary loop, horseshoe shaped. Arterioles and venules measuring 50 microns in the larger diameter, which is characteristic of SS or a mixed disease of connective tissue disorder and dermatomyositis.
Intercapillary distance	The increased distance between two neighbor loops, could be an early sign of avascularity
Avascularity	Absence of capillary loops, more or less severe
Micro hemorrhage	Produced by capillary disruption and bleeding on the adjacent dermis, which is observed as red or brownish points, close to the capillary apex, later turning into hemosiderine deposits



**Figure 4:** Nail fold video capillaroscopy (200X). Preserved capillary bed structure and normal density. Increased intercapillary distance.



**Figure 3:** Nail fold video capillaroscopy (200X). Nail bed structure preserved, corresponding to 1 mm. Normal density. In the left side, the image of mega capillaries.



**Figure 5:** Nail fold video capillaroscopy (400X). Giant vessels larger than 1 Micron, one with much dilated walls and the other with cyanosis and granular flow. Hemosiderine deposits close to the capillary apex due to an old micro hemorrhage.

The acrocyanosis as an isolated sign in elderly male is not pathognomonic of systemic sclerosis or related disorders.

## References

1. Kurklsinsky AK, Miller VM, Rooke TW (2011) Acrocyanosis: The Flying Dutchman. *Vasc Med* 16: 288-301.
2. Ingegnoli F, Gualtierotti R, Mastaglio C, Meroni PL, Boracchi P, et al. (2015) Uniphasic Blanching of the Fingers, Abnormal Capillaroscopy in Nonsymptomatic Digits, and Autoantibodies: Expanding Options to Increase the Level of Suspicion of Connective Tissue Classification of Raynaud's phenomenon. *J Immunol Res* 371960.
3. Affandi AJ, Radstake TRDJ, Marut W (2015) Update on biomarkers in systemic sclerosis: tools for diagnosis and treatment. *Semin Immunopathol* 37: 475-487.
4. McMahan ZH, Wigley FW (2010) Raynaud's phenomenon and digital ischemia: a practical approach to risk stratification, diagnosis and management. *Int J Clin Rheumtol* 5: 355-370.
5. Ingegnoli F, Gualtierotti R, Orenti A, Schioppo T, Marfia G, et al. (2014) Nail fold videocapillaroscopy micro-hemorrhages and giant capillary counting as an accurate approach for a steady state definition of disease activity in systemic sclerosis. *Arthritis Res Ther* 16: 462-468.

**Copyright:** © 2016 Leroux MB. This is an open-access article distributed under the terms of the Creative Commons Attribution License, which permits unrestricted use, distribution, and reproduction in any medium, provided the original author and source are credited.

**Citation:** Leroux MB (2016) Nail Fold Capillaroscopic Findings in Elderly Patient with Acrocyanosis. *Int J Dermatol Clin Res* 2(1): 001-002. DOI: 10.17352/2455-8605.000012