

Hossein Mostafa Elbadawy^{1*},
Alessandro Ruzza¹, Mohit Parekh¹,
Davide Camposampiero¹, Marina De
Rossi¹, Sandro Sbordone², Stefano
Ferrari¹ and Diego Ponzin¹

¹International Centre for Ocular Physiopathology (ICOP), the Veneto Eye Bank Foundation Italy
²Eye department, Second University of Naples, Italy

Dates: Received: 29 December, 2014; Accepted: 21 February, 2015; Published: 23 February, 2015

*Corresponding author: ElbadawyH M, PhD, The Veneto Eye Bank Foundation, Via Paccagnella 11, Padiglione Rama, Mestre, Venice, 30174, Italy, Tel: 00393200937283; Fax: 0039 041 965 6471; E-mail: hossein.elbadawy@fbov.it

www.peertechz.com

Keywords: Keratoconus; Neovascularisation; Albinism; Cornea

ISSN: 2455-1414

Case Report

Optical Coherence Tomography for the Identification of a Rare Case of Keratoconus in Albino Donor Cornea

Abstract

A 61 years old albino donor cornea shows an association of a triple corneal pathologies, keratoconus, oculocutaneous albinism and neovascularisation. Optical coherence tomography (OCT) showed severe signs of keratoconus, corneal vascularisation and the presence of central leukoma. Keratoconus and corneal vascularisation in albino patients is a unique association, however, the genetic basis of this combination is still unclear.

albinism, keratoconus and corneal vascularisation were not reported previously.

Case Presentation

The corneas from a 61 years old albino donor were recovered by The Veneto Eye Bank Foundation, Italy. The donor had a history of positive hypercholesterolemia and hypertension, and silent for corneal disorders. The cause of death was myocardial infarction. The autopsy revealed cardiac hypertrophy, myocardial diffuse sclerosis, hypoxic myocardial damage, outbreak of lymphocytic infiltration between cardiac myocytes, in multivessel coronary atherosclerosis plaques with regional myocardial ischemia and coronary spasm with critical stenosis of the left anterior descending branch. Pulmonary congestion and haemorrhagic alveoli with sub-acute multiorgan stasis were also evident. The patient was heterochromic with green right and blue left eyes. The deceased was pseudophakic with KC in both eyes (Figure 1a) and central leukoma (Figure 1b). Trypanblue® staining was positive in few areas of the epithelium and the stroma near the centre of the cornea. The cornea from the right eye was used for OCT

Introduction

Keratoconus (KC) is a corneal ectatic disorder characterized by irregular corneal surface elevation, interruptions in the Bowman's layer, stromal thinning and degeneration [1-3]. Irregular astigmatism and myopia can cause severe visual impairment. Oculocutaneous albinism (OCA) is a group of inherited disorders of melanin biosynthesis characterized by a generalized reduction in pigmentation of hair, skin and eyes. The inheritance pattern of albinism is autosomal recessive. Mutations in the tyrosinase [TYR] gene on chromosome 11 q14-q21 are reportedly common in most cases of OCA. The inheritance patterns of keratoconus are more complex than albinism due to the involvement of environmental factors in the incidence of KC. The most studied gene involved in KC is VSX1 gene, which is also involved in other corneal dystrophies [4]. Clinical manifestations of albinism include various degrees of congenital nystagmus, hypopigmentation and refractive errors, however, the association of

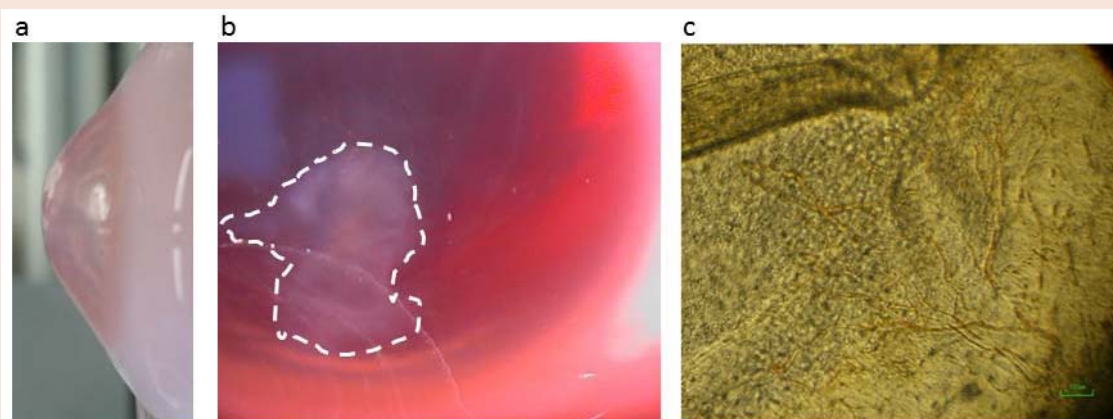


Figure 1: a) Elevated central corneal surface, typical for keratoconus. b) Slit lamp at 10x magnification of the cornea, preserved at 4°C, showing central leukoma (outlined) which extends to the periphery; c) Light microscope 100x magnification remarking the presence of corneal vascularisation behind the stromal haze.

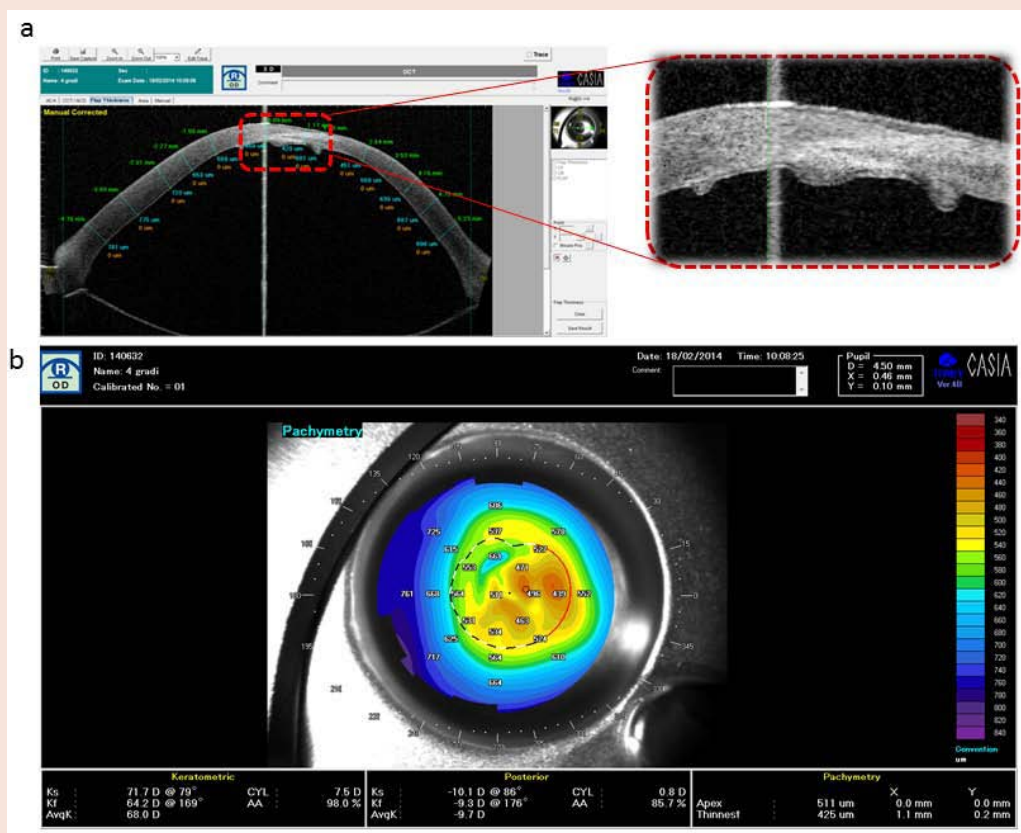


Figure 1: a) Elevated central corneal surface, typical for keratoconus. b) Slit lamp at 10x magnification of the cornea, preserved at 4°C, showing central leukoma (outlined) which extends to the periphery; c) Light microscope 100x magnification remarking the presence of corneal vascularisation behind the stromal haze.

scanning. An abrupt incline of the corneal surface near the centre and thinning of the central stroma was noted (Figure 2). Additionally, vascularisation was evident behind the stromal haze (Figure 1c). The endothelium had large wrinkles and the leukoma was concentrated in the thinnest area of the cornea.

Discussion

The association of albinism and KC was reported in a patient with bilateral KC associated with photophobia, positive family history for albinism and a history of frequent rubbing of the eyes [5], which has been put in relation with KC [6]. The locations of the TYR and VSX1 genes are on different chromosomes and hence are not expected to have common mutations, however, no association of VSX1 mutations with KC was found in a study performed on a large number of patients, hence, the genetic basis of KC requires further investigation [7]. The histopathology of albinism associated KC, shown here for the first time using OCT, can help diagnose and further understand the structural variations in diseased corneas. Additionally, it is shown here for the first time the association of KC and vascularization of the stroma, however, the genetic basis of this combination remains

unknown. No information was found in the patient's history about any previous injury or trauma to the cornea.

References

- Rabinowitz YS (1998) Keratoconus. *Surv ophthalmol*42:297-319.
- Chi HH, Katzin HM, Teng CC (1956) Histopathology of keratoconus. *Am J Ophthalmol*42:847-860.
- Sherwin T, Brookes NH (2004) Morphological changes in keratoconus: pathology or pathogenesis. *Clin Exp Ophthalmol* 32: 211-217.
- Héon E1, Greenberg A, Kopp KK, Rootman D, Vincent AL, et al. (2002) VSX1: a gene for posterior polymorphous dystrophy and keratoconus. *Hum Mol Genet* 11: 1029-1036.
- Rao VA, Swathi P, Thappa DM (2008) Bilateral keratoconus with oculocutaneous albinism. *Indian J Dermatol Venereol Leprol* 74: 407-409.
- Lindsay RG, Bruce AS, Gutteridge IF (2000) Keratoconus associated with continual eye rubbing due to punctal agenesis. *Cornea* 19:567-569.
- Aldave AJ, Yellore VS, Salem AK, Yoo GL, Rayner SA, et al. (2006) No VSX1 gene mutations associated with keratoconus. *Invest Ophthalmol Vis Sci* 47: 2820-2822.

Copyright: © 2015 Elbadawy HM, et al. This is an open-access article distributed under the terms of the Creative Commons Attribution License, which permits unrestricted use, distribution, and reproduction in any medium, provided the original author and source are credited.

Citation: Elbadawy HM, Ruzza A, Parekh M, Camposampiero D, De Rossi M, et al. (2015) Optical Coherence Tomography for the Identification of a Rare Case of Keratoconus in Albino Donor Cornea. *J Clin Res Ophthalmol* 2(2): 028-029. DOI: 10.17352/2455-1414.000014